

# RE-TORAKOTOMİ RE-KOARKTASYON VE HİPOPLASTİK AORT ARKUSUNU DÜZELTMEK İÇİN UYGUN BİR YÖNTEM Mİ?

## IS RE-THORACOTOMY CONVIENENT APPROACH IN CORRECTING RE-COARCTATION AND HYPOPLASTIC AORTIC ARCH?

Ahmet SARITAŞ, Kanat ÖZİŞİK, Ayşenur PAÇ, İrfan TAŞOĞLU, Şeref Alp KÜÇÜKER, Mustafa PAÇ

### OLGU SUNUMU

#### ÖZET

Dokuz yaşında 24 kg erkek hasta re-aort koarktasyonu ve aortik ark hipoplazisi cerrahisi için hastanemize başvurdu . Hastaya 4 yıl önce reseksiyon ve uç uca anastomoz tekniği ile aort koarktasyonu onarımı yapılmıştı. Bilgisayarlı tomografi anjiyografi'de eski tamir bölgesinde belirgin daralma görüldü ve aortik ark hipoplazisi teyit edildi. Sol re-torakotomiden sonra, aort devamlılığını sağlamak için bir Dacron yama yerleştirdi. Ameliyat sonrası dönemi sorunsuz geçiren hasta ameliyatın yedinci gününde taburcu edildi. Post-operatif dönemde yapılan kontrol bilgisayarlı tomografi anjiyografi'de greftin açık olduğu izlendi.

**Anahtar kelimeler:** Aort koarktasyonu, aortik ark hipoplazisi, cerrahi, re-torakotomi

### INTRODUCTION

Re-coarctation of the aorta (re-CoA) is not uncommon and is dependent on age at first operation, anatomy of the aorta, length of the abnormal tissue resected and the type of surgical procedure performed (1). The presence of a aortic arch hypoplasia (AAH) has been identified as one of the most important risk factor for reintervention in patients with CoA. One reason fort his may be underdiagnosed AAH and consecutive less aggressive treatment at primary surgery. Re-CoA may be difficult to manage when associated with tubular AAH, calcification and tissue adhesives. In case of

### CASE REPORT

#### ABSTRACT

A nine-year-old boy weighing 24 kg referred to our hospital for surgical treatment of re-coarctation of the aorta and aortic arch hypoplasia. He had a history of resection of coarctation of the aorta with end-to-end anastomosis 4 years before. Computerized tomography angiography of the chest revealed obvious narrowing at the repaired site and confirmed the aortic arch hypoplasia. Following a left re-thoracotomy, a Dacron patch graft was used to restore aortic continuity. The postoperative course was uneventful and the patient was discharged on the seventh postoperative day. Post-operative control computerized tomography angiography confirmed the patency of the patch plasty .

**Key words:** Aortic coarctation, aortic arch hypoplasia, surgery, re-thoracotomy

concomitant AAH, deep hypothermic circulatory arrest is needed for augmentation of re-CoA, which expose patients to increased cerebrovascular risks (2). In this patient, following a left re-thoracotomy, a Dacron patch graft was used to restore aortic continuity.

### CASE REPORT

A nine-year-old boy weighing 24 kg referred to our hospital for surgical treatment of re-CoA and AAH. Physical examination was completely normal except both femoral and left upper extremity pulses were weak. Four years before, he has been operated for CoA

Geliş Tarihi/Received: 23/01/2010 Kabul Tarihi/Accepted: 07/03/2010

#### İletişim:

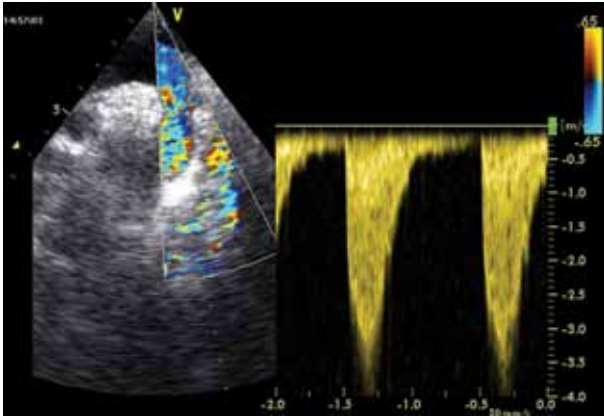
**Kanat Ozisik, MD**

Birlik mah. 450. Cad.Vadi Apt. No:107/12 06550 Ankara- TURKEY

**Tel:** +90-505- 2901885 **Fax:** +90-312-3170353 **E-mail:** sozisik2002@yahoo.com

through a left lateral thoracotomy in another center. A 15-mm segment of narrowed isthmus was resected and the descending thoracic aorta was pulled superiorly and directly anastomosed to the proximal part of the aortic arch.

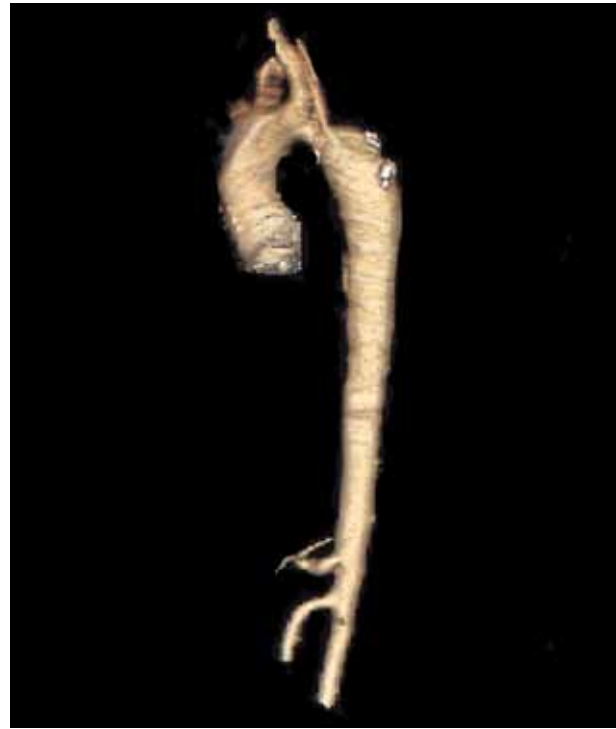Electrocardiogram showed normal sinus rhythm. Echocardiography demonstrated AAH between brachiocephalic artery and left subclavian artery, and re-CoA with a mean gradient of 40 mmHg at the region where surgery had been previously performed (Figure 1A). The aortic valve was bicuspid. Cardiac catheterisation and angiography also demonstrated a small transverse aortic arch after brachiocephalic artery and dilated descending thoracic aorta.



**Figure 1A-** Preoperative echocardiography demonstrates re-CoA and AAH with a gradient of 40 mmHg.

Computerized tomography (CT) angiography of the chest revealed obvious narrowing at the repaired site and confirmed the AAH. Subclavian artery was demonstrated as originating from the descending aorta beyond the hypoplastic segment (Figure 1B).

Elective surgical treatment of the re-CoA was planned and extreme care was taken for the dissection of the distal aortic arch and the proximal descending aorta because of the possible increased friability of the arterial wall and adhesions through a redo left thoracotomy. The left common carotid artery and the subclavian artery were gently clamped and the proximal descending artery and aortic arch were cross-clamped between the brachiocephalic artery and the left common carotid artery. A longitudinal incision was performed in the concavity of the aortic arch (across the re-CoA segment). He underwent aortic enlargement with a perpendicular Dacron patch in order to increase vertical distensibility.

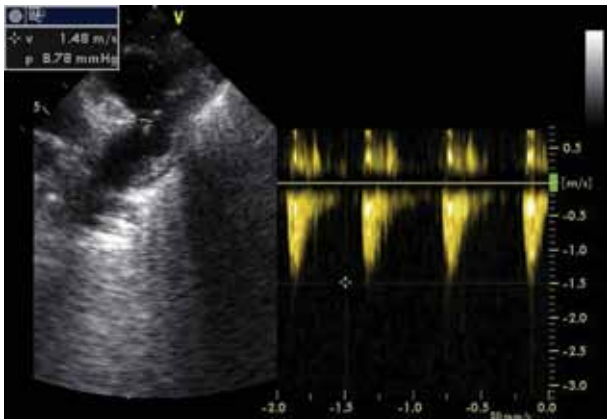


**Figure 1B-** Preoperative CT angiography showing re-CoA segment and diffuse stenosis of the AAH.

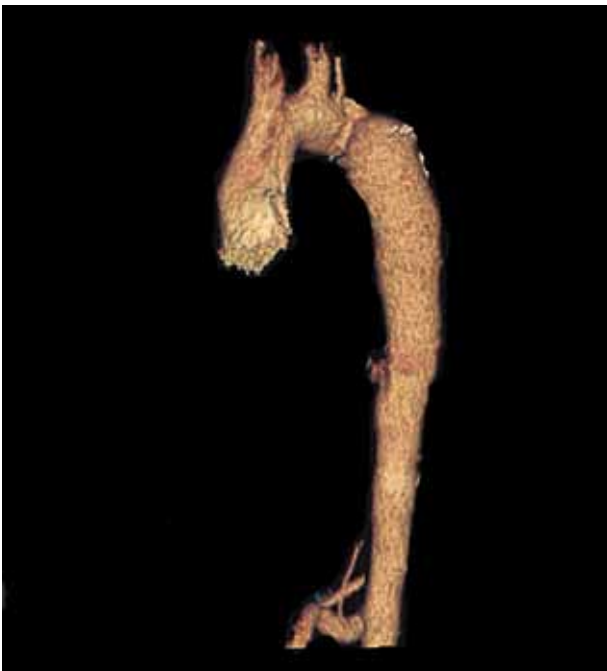Once the repair of re-CoA and AAH was completed, the aorta was deaired, the clamps on the arch arteries were removed and normal perfusion was resumed. Following deaeration clamps were released. Pulsatile blood flow was palpated in the descending thoracic aorta, distal to the patch plasty. The blood flow of right carotid artery was satisfactory therefore the shunt was not used. Blood pressure measured intra-operatively at proximal and distal segment showed no gradient across the corrected re-CoA and early follow-up echocardiograms demonstrated a harmonious reconstruction of the aortic arch and an unobstructed blood flow (Figure 2A). Blood pressure gradient between the right upper extremity and bilateral lower extremities reduced to 10 mmHg. Post operative control CT angiography confirmed the patency of the patch plasty and success of the operative procedure (Figure 2B).

## DISCUSSION

Backer et al. have reported that the rate of re-CoA after extended end to end anastomosis is 4% to 23%(3). In this situation, the procedure of choice is percutaneous balloon dilatation and stenting; however, with presence of calcification, tissue adhesives and diffuse



**Figure 2A-** Dacron Patch plasty with no stenosis and gradient showed by postoperative echocardiography.



**Figure 2B-** Postoperative CT angiography showing an excellent result after insertion of a Dacron patch plasty.

tubular AAH this approach may not be recommended (4).

The best surgical repair management of re-CoA and AAH is controversial in children. Prosthetic patch aortoplasty is a safe operation. The mortality rate and incidence of paraplegia after patch aortoplasty are extremely low (5). The operative mortality in several series ranges from 0% to 10% (6,7). The technique avoids extensive dissection and prolonged cross-clamp time that may be required for CoA resection and end to end anastomosis. The collateral vessels are all preserved and

do not require ligation or division. The anastomosis is always tension free and quite easy to perform. Dacron patch aortoplasty is our procedure of choice because it provides excellent relief of CoA with a very low mortality rate, a low re-CoA rate. Long-term follow up is needed to allow a more definitive comparison with other established treatment modalities.

Surgery is usually performed via sternotomy and distal exposure of the aorta is limited to the isthmic region. In surgical treatment of long segment restenosis with sternotomy possible difficulties are a need for distal extension of the patch and inefficient mobilization of the descending aorta. In our case, exposure through a left re-thoracotomy was considered for local dissection of adhesions with a risk of injury to adjacent anatomical structures or the diseased aorta.

The simple implantation of an extra-anatomic bypass has resulted in good results and accepted as a safe surgical approach in adults (2,8). Long term results of this repair and the consequences to cardiac physiology are, however, unknown. Major limitations of ascending to descending aortic bypass are the age of the patient and the size of the aorta (9). We believe that this approach is not indicated in children and infants. Furthermore, a left thoracotomy approach may be applicable for redo surgery in this age group, because extra-anatomic bypass methods may be not enough for a growing child at later decades.

On the other hand, sternotomy was spared for a late aortic valve intervention which may secondarily occur because of a bicuspid aortic valve, in this patient.

## REFERENCES

1. Kappetein AP, Zwinderman AH, Bogers AJ, Rohmer J, Huysmans HA. More than thirty-five years of coarctation repair. An unexpected high relapse rate. *J Thorac Cardiovasc Surg* 1994;107:87-95.
2. Berdat PA, Göber V, Carrel T. Extra-anatomic aortic bypass for complex (re-) coarctation and hypoplastic aortic arch in adolescents and adults. *Interact Cardiovasc Thorac Surg* 2003;2:133-7.
3. Backer CL, Mavroudis C, Zias EA, Amin Z, Weigel TJ. Repair of coarctation with resection and extended end-to-end anastomosis. *Ann Thorac Surg* 1998;66:1365-70.
4. Magee AG, Brzezinska-Rajszyz G, Qureshi SA, Rosenthal E, Zubrzycka M, Ksiazek J, et al. Stent implantation for aortic coarctation and recoarctation. *Heart* 1999;82:600-6.
5. Backer CL, Paape K, Zales VR, Weigel TJ, Mavroudis C. Coarctation of the aorta. Repair with

- polytetrafluoroethylene patch aortoplasty. *Circulation* 1995;92(9 Suppl):II132- II136.
6. Sade RM, Crawford FA, Hohn AR, Riopel DA, Taylor AB. Growth of the aorta after prosthetic patch aortoplasty for coarctation in infants. *Ann Thorac Surg* 1984;38:21-5.
  7. Ungerleider RM. Is there a role for prosthetic patch aortoplasty in the repair of coarctation? *Ann Thorac Surg* 1991;52:601-2.
  8. Harmandar B, Ugurlucan M, Sayin OA, Tohumcu UT, Toker A, Tireli E. Ascending aorta-to-descending aorta bypass via right thoracotomy for the re-coarctation of the aorta: An alternative surgical approach for re-coarctation. *J Card Surg* 2007;22:58-60.
  9. Schoenhoff FS, Berdat PA, Pavlovic M, Kadner A, Schwerzmann M, Pfammatter JP, et al. Off-pump extraanatomic aortic bypass for the treatment of complex aortic coarctation and hypoplastic aortic arch. *Ann Thorac Surg* 2008;85:460-4.